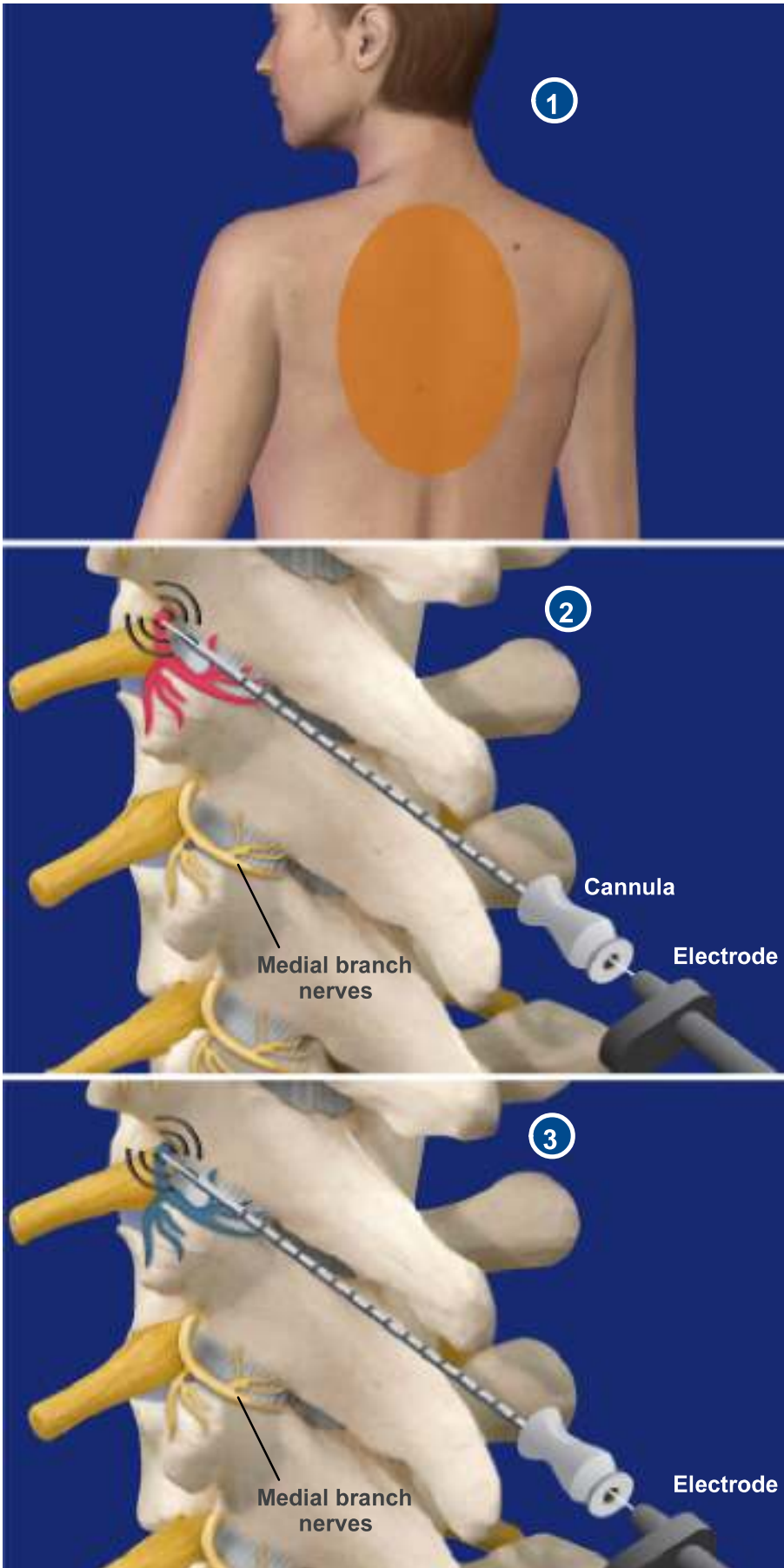


THORACIC FACET RADIOFREQUENCY NEUROTOMY



This minimally-invasive procedure, also called radiofrequency (or RF) rhizotomy, reduces or eliminates the pain of damaged facet joints by disrupting the medial branch nerves that carry the pain signals. This procedure is performed with local anesthetic.

1. Preparation

The patient lies face down, and the back is cleaned and sterilized. Local anesthesia is administered to numb the tissue at the injection site down to the spinal column.

Inserting the Cannula

The physician uses an x-ray device called a fluoroscope to carefully guide a needle-like tube called a cannula to the irritated medial branch nerves.

2. Injecting the Radiofrequency Electrode

A radiofrequency electrode is inserted through the cannula. The physician tests the electrode's position by administering a weak electric stimulation. If the stimulation recreates the pain without any other muscular effects, the electrode is positioned correctly.

3. Heating the Nerve

The physician uses the electrode to heat and cauterize the nerve. This disrupts its ability to communicate with the brain, blocking the pain signals. Multiple nerves may require treatment.

End of Procedure

The electrode and cannula are removed, and the injection site is covered with a small bandage. Although pain may increase for the first week after the procedure, the patient usually has full relief from pain within a month. Successful RF neurotomies can last longer than steroid block injections.